

two different locus of linguistic impairment and use distinct brain mechanisms to overcome their deficits. Verb retrieval per se was relatively spared in P1 and P2, as follows from their naming scores. It was motor execution of the word that caused difficulties in them. The effort to overcome those difficulties resulted in specific activation in the right cerebellum, which is known to be a regulator of speech temporal sequencing. In contrast, P3 and P4 had intrinsic linguistic difficulties with verb finding and used wide-spread bilateral frontotemporal network to overcome them.

Thus, in addition to the identification of brain substrate involved in normative verb production, the present study showed how different loci of linguistic deficits within the same aphasia syndrome are represented in distinct cerebrocerebellar networks.

Lobar localization information in epilepsy patients: comparison between long-term video-EEG monitoring and MEG

Koptelova A.M.¹ /koptelova.am@gmail.com/, Melikian A.G.², Arkhipova N.A.², Stepanenko A.Y.³, Golovtsev A.L.², Kozlova A.B.², Grinenko O.A.², Stroganova T.A.¹

¹ *MEG-center, Moscow State University of Psychology and Education, Moscow, Russia*

² *The Burdenko Neurosurgery Institute, Moscow, Russia*

³ *Department of Neurosurgery, Moscow City Hospital No 12, Moscow, Russia*

Purpose. Magnetoencephalography (MEG) and magnetic source imaging (MSI) are techniques that have been increasingly used for preoperative localization of epileptic foci. To help elucidate the value of MEG, we assessed the results of whole-head MEG versus video-EEG (vEEG) in the case management of patients undergoing epilepsy surgery.

Method. We studied 19 patients with suspected focal epilepsy who underwent interictal and ictal vEEG and, subsequently, interictal and ictal MEG. Out of 19 patients studied 14 were with suspected neocortical epilepsy, 5 with with mesial temporal lobe epilepsy. Nine patients underwent surgical resection of suspected epileptogenic zone and seven of them – invasive electrocorticography (ECoG). The results of MSI were classified to define epileptogenic foci according to the clustering of interictal and ictal spikes recorded during a 4-hour recording session. The data were analyzed to determine to what extent the results of MSI correlated with vEEG determined irritative zones.

Results. In 4 of 19 cases MSI – determined localization regionally correlated with vEEG data (that is, showed the same lobe). In fifteen patients MSI showed 32 additional epileptogenic foci that interictal vEEG was unable to identified. These undetected sources were localized mainly in the frontal and temporal lobes (70%), and at the lobar surface level - at the medial and the basal aspects of cerebral lobes (70%). In six cases, MSI

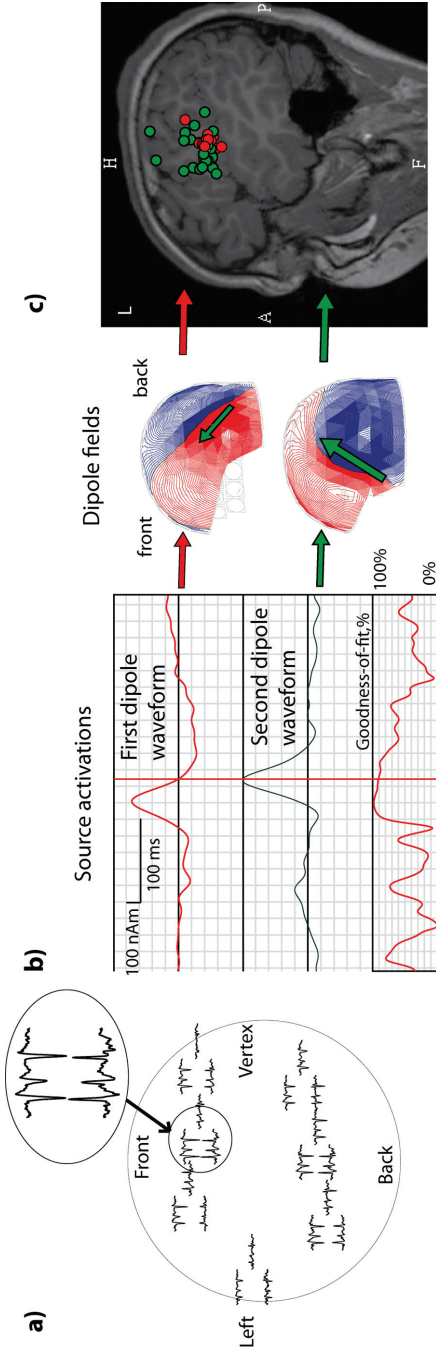


Fig. 1. An example of magnetoecephalographic localization of epileptic foci in a patient - a candidate for epilepsy surgery. Spikes following one after another with 25 ms delay are seen at two orthogonal MEG-sensors (a).

Spikes were modelled by two dipole sources that activated sequentially (b).

The results of source modelling for multitude of such «paired» spikes (c) implied that the sources of first spike in a pair formed a compact cluster (red circles) around ventral edge of left central sulcus. The sources of the second spike in a pair were more widespread (green circles) and appeared to result from propagation of epileptic discharge.

was used to guide invasive electrodes to locations that otherwise would not have been targeted and provided unique localization data, not evident from other imaging modalities, that strongly influenced the surgical management of the patient. In seven patients, for whom data from invasive ECoG were available, the MSI was highly correlated with the zone of seizure origin identified by EcoG.

Conclusion. Magnetic source imaging can provide critical localization information that is not available when other noninvasive methods, such as vEEG and MRI, are used.

Auditory cortex responses to clicks and sensory modulation abnormalities in children with autism spectrum disorders (ASD)

*Orekhova E.V.¹ /elena.orekhova@neuro.gu.se/, Tsetlin M. M.²,
Butorina A.V.², Novikova S.I.², Gratchev V.V.³, Sokolov P.A.⁴,
Elam M.¹, Stroganova T. A.²*

¹ *Institute of Neuroscience and Physiology, University of Gothenburg, Gothenburg, Sweden*

² *MEG-center, Moscow State University of Psychology and Education, Moscow, Russia*

³ *Clinical Department for the Study of Adolescent Psychiatry, Mental Health Research Center of Russian Academy of Medical Sciences, Moscow, Russia*

⁴ *Moscow Pediatric Center, Moscow, Russia*

Auditory sensory modulation difficulties are common in autism spectrum disorders (ASD) and may stem from a faulty arousal system that compromises the ability to regulate an optimal response. To study neurophysiological correlates of the sensory modulation difficulties, we recorded magnetic field responses to clicks in 14 ASD and 15 typically developing (TD) children. We further analyzed the P100m, which is the most prominent component of the auditory magnetic field response in children and may reflect preattentive arousal processes. The P100m was rightward lateralized in the TD, but not in the ASD children, who showed a tendency toward P100m reduction in the right hemisphere (RH). The atypical P100m lateralization in the ASD subjects was associated with greater severity of sensory abnormalities assessed by Short Sensory Profile, as well as with auditory hypersensitivity during the first two years of life. After correction for IQ, the RH P100m amplitude tended to correlate negatively with severity of autism symptoms in the ASD group ($p=0.06$). The P100m reduction in the RH in the ASD children suggests disturbance of the RH ascending reticular brainstem pathways and/or their thalamic and cortical projections, which in turn may contribute to abnormal arousal and attention. The correlation of sensory abnormalities with atypical, more leftward, P100m lateralization suggests that reduced preattentive processing in the right hemisphere and/or its shift to the left hemisphere may contribute to abnormal sensory behavior in ASD.